



# Cirrhosis: A Red Flag When Treating Cellulitis

James Malcolm PhD Andrew Webster MD Rumman Langah MD, FACP



## Learning Objectives

Recognize cirrhosis and other immunocompromised states as a risk factor for uncommon gram negative cellulitis.

## Case

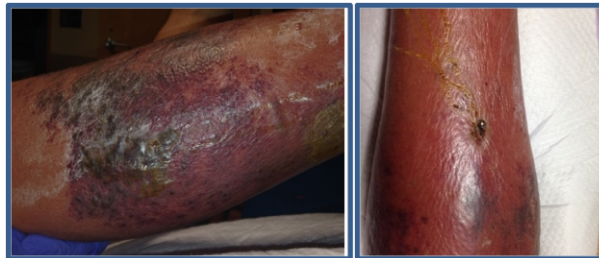
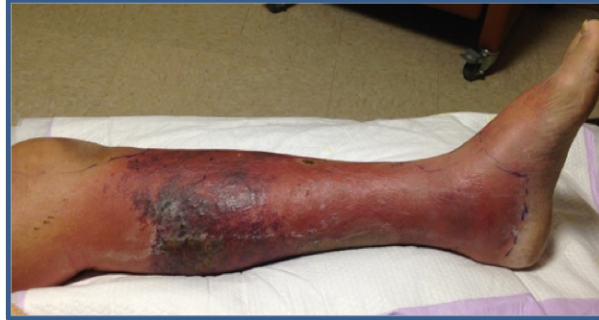50 year old male developed left lower leg erythema, pain and swelling for several days following small scratch wound. He failed outpatient cephalexin. Later, admitted to outside hospital and treated with vancomycin plus ertapenem with some response, and discharged on daptomycin monotherapy. He presented to our ER with worsening symptoms and signs, as shown.

**PMH:** Alcoholic cirrhosis

**VS:** T37.6, HR 94, BP 150/93

**Labs:** Tbili 3.3, AST 68, ALT 40, Alb 1.8, INR 2.19, WBC 6.7, Plt 63, MELD 20

## Hospital Course



We placed him on vancomycin , piperacillin/tazobactam, and clindamycin with significant response. Antibiotics narrowed to cefepime monotherapy, while he continued to improve, and discharged on oral levofloxacin with close PCP followup.

## Discussion

Cirrhosis causes immune dysfunction from impaired IgM antibody function, compliment deficiency, decreased PMNs, and decreased Kupffer cells. This causes increased susceptibility to Gram negative bacteria, most commonly E coli, Pseudomonas, Klebsiella, and Aeromonas.

## Conclusion

Gram-positive coverage is usually sufficient in most cases of cellulitis but this case emphasizes that special attention be given to the possibility of gram negative bacillus infection in cirrhotic patients, particularly when first-line empiric therapy shows no improvement.

Wyke RJ. *Gut.* 1987;28:623-641.

Horowitz Y, Sperber AD, Almog Y. *Mayo Clin Proc.* 2004 Feb;79(2):247-50.