



Cortical Trajectory Screw Placement for Transforaminal Lumbar Interbody Fusion

James Malcolm, Michael Moore and Daniel Refai*

Department of Neurosurgery, Emory University, USA

Clinical Image

A 72-year-old female was presented with two-level posterior arthrodesis using cortical-trajectory screws with transforaminal interbody spacers (Figure 1). Along the top row, AP & lateral plain films show a medial-to-lateral and superior screw trajectory. In the bottom, axial CT again shows the medial-to-lateral trajectory with good purchase in cortical bone. Biomechanical studies have shown that this trajectory increases contact between the screw threads and cortical bone leading to improved implant interface and increased pull-out load over traditional pedicle screws. Further, by starting from a more midline approach, the cortical trajectory minimizes lateral dissection, blood loss, pain, and rehab needs.

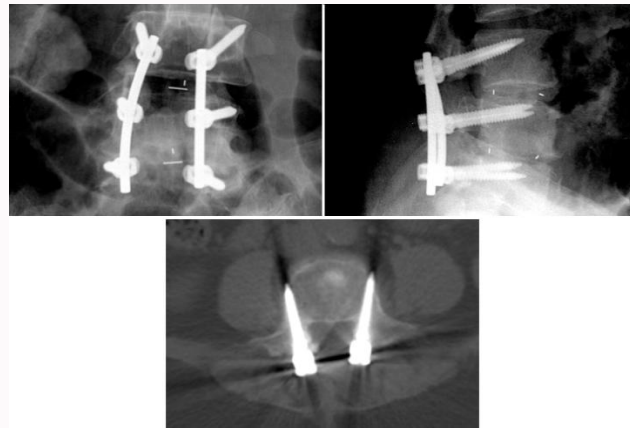


Figure 1: Two-level posterior arthrodesis using cortical-trajectory screws with transforaminal interbody spacers.

OPEN ACCESS

*Correspondence:

Daniel Refai, Department of Neurosurgery, Emory University, 1365 Clifton Road NE, Suite B6200, Atlanta, GA 30322, USA, Tel: 404-778-5000; Fax: 404-778-4472;

E-mail: daniel.refai@emory.edu

Received Date: 02 May 2017

Accepted Date: 17 May 2017

Published Date: 25 May 2017

Citation:

Malcolm J, Moore M, Refai D. Cortical Trajectory Screw Placement for Transforaminal Lumbar Interbody Fusion. *Ann Neurol Surg.* 2017; 1(1): 1002.

Copyright © 2017 Daniel Refai. This is an open access article distributed under the Creative Commons Attribution License, which permits unrestricted use, distribution, and reproduction in any medium, provided the original work is properly cited.