

# Role of diffusion tensor imaging in predicting post-operative outcome in cervical degenerative pathologies: *A systematic review of the literature*

Rima S. Rindler<sup>1</sup>, M.D.; Falgun Chokshi, MD<sup>2</sup>; James M. Malcolm, PhD<sup>1</sup>;  
Sheila R. Eshraghi, MD<sup>1</sup>; Mahmud Mossa-Basha, MD, DABR<sup>3</sup>; Jason  
Chu, MD<sup>1</sup>; Faiz Ahmad, MD, MCh<sup>1</sup>

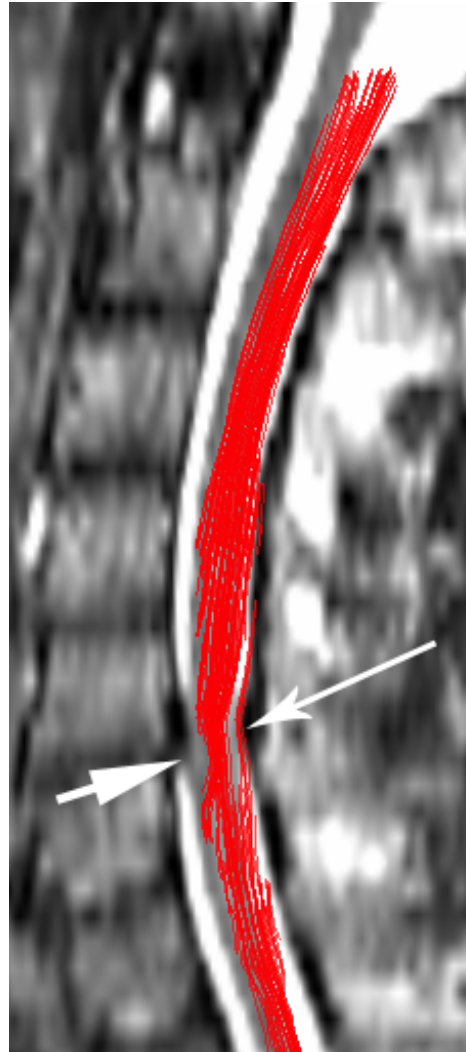
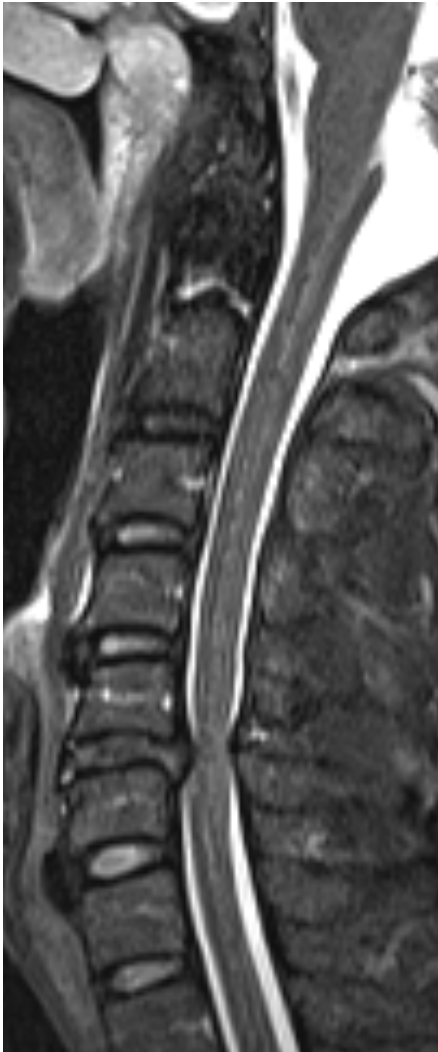<sup>1</sup>Department of Neurological Surgery, Emory University School of Medicine, Atlanta, Georgia, United States of America

<sup>2</sup>Department of Radiology and Imaging Sciences, Emory University School of Medicine, Atlanta, Georgia, United States of America;

<sup>3</sup>Department of Radiology, University of Washington, Seattle, Washington, United States of America



EMORY  
UNIVERSITY



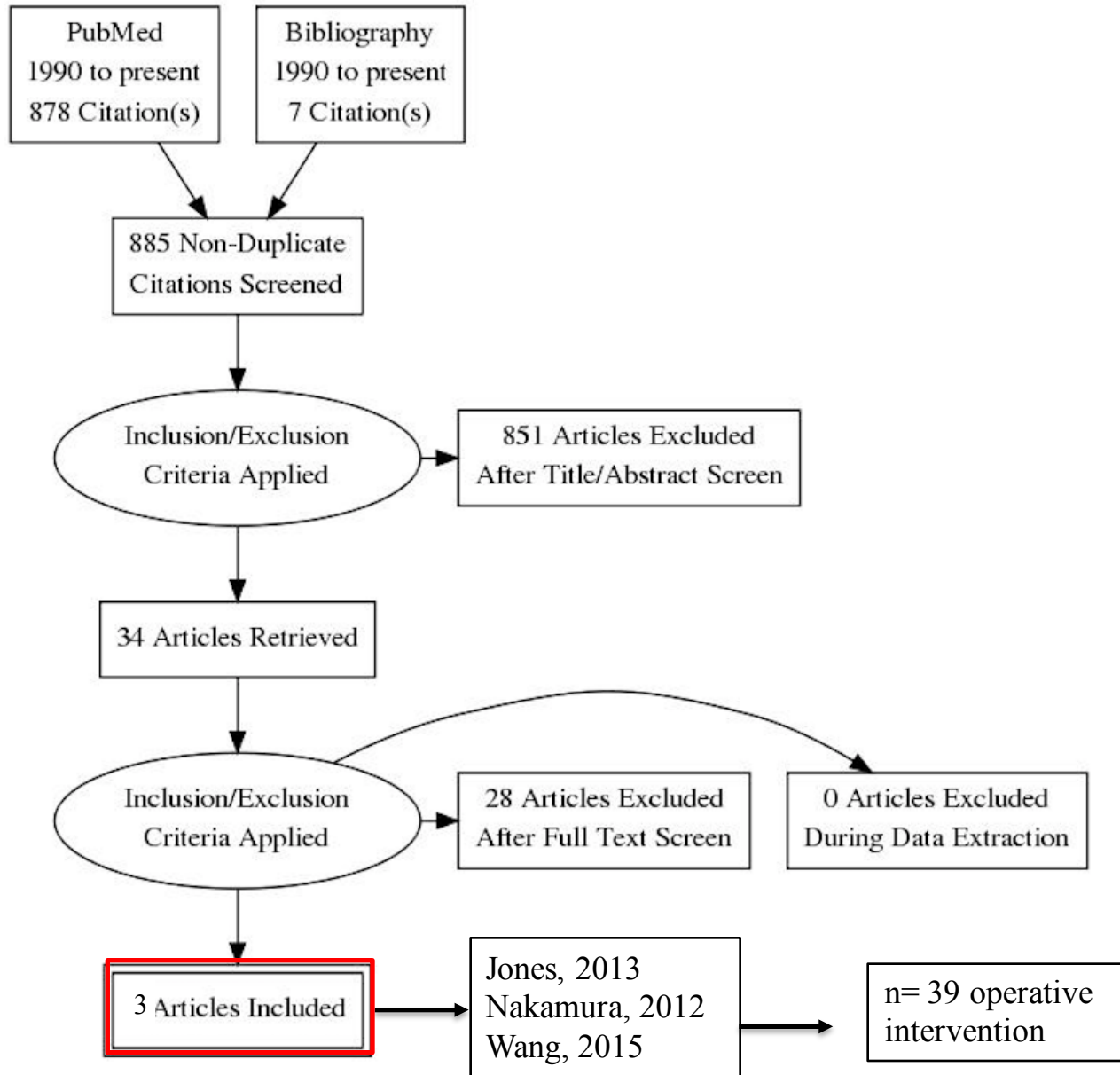
↓ Fractional Anisotropy (FA)

↑ Apparent Diffusion Coefficient (ADC)

Tractography



# PRISMA Flow Diagram



# DTI predicts post-operative outcome

Author and Year	FA				FTR/Tractography
	Modified Japanese Outcome Assessment	Neck Disability Index	Nurick Scale	Short Form-39	Modified Japanese Outcome Assessment
Jones, 2013	0.06, p=0.84	-0.61; p=0.04	-0.22, p=0.44	0.52, p=0.51	
Nakamura, 2012					0.6066, p=0.0046
Wang, 2015				<sup>a</sup> -0.40, p>0.6	



DTI predicts post-operative outcome in patients with cervical spondylotic myelopathy.

