



Case report

Early urgent cranioplasty for symptomatic hygroma: Report of two cases



James G. Malcolm, Brandon A. Miller, Jonathan A. Grossberg, Gustavo Pradilla, Faiz U. Ahmad*

Department of Neurological Surgery, Emory University, Atlanta, GA, United States

ARTICLE INFO

Article history:

Received 21 June 2016

Accepted 1 August 2016

Keywords:

Craniectomy

Cranioplasty

Hygroma

Early

Timing

ABSTRACT

Following craniectomy, hygromas are relatively common. While many cases resolve spontaneously, some patients develop neurologic deficits. Management of symptomatic hygromas often involves shunting or drainage. We present two patients who three weeks after decompressive hemicraniectomy developed declining neurologic status secondary to enlarging hygroma. Failing conservative management, both were treated with urgent cranioplasty and returned to neurologic baseline. Early cranioplasty may be safe and effective for symptomatic collections.

© 2016 Elsevier Ltd. All rights reserved.

1. Introduction

Following decompressive craniectomy patients remain at risk for hemorrhage, infection, cerebrospinal fluid (CSF) disturbances, and are vulnerable to trauma before cranioplasty [1]. Specific complications tend to occur in a predictable time course with hemorrhage and fluid collections occurring in the weeks following craniectomy and paradoxical herniation occurring after months [2,3]. Standard practice is to delay cranioplasty until edema, extra-axial fluid collections, or infection have resolved, often a delay of several months [4]. Cranioplasty has been shown to improve neurologic function and some argue that it should be performed earlier to enhance rehabilitation [5]. While some surgeons wait a minimum period before cranioplasty, a review found no association between complications and timing [6].

2. Case 1

A 43-year-old male suffered a ground level fall. His Glasgow Coma Scale (GCS) was 15 on arrival yet imaging demonstrated a subdural hematoma and intraparenchymal hemorrhages (Fig. 1A). We performed emergent hemicraniectomy and extraventricular drain (EVD) placement.

Postoperatively, he remained intubated with GCS 6T. His craniectomy flap remained sunken and intracranial pressure

within normal limits (Fig. 1B). His EVD was removed after four days. His neurological exam slowly improved, however he was unable to be weaned from the ventilator.

Two weeks after his craniectomy his neurologic exam declined. His GCS remained 6T but his craniectomy flap was full and tense. Imaging revealed a large hygroma with midline shift (Fig. 1C). This was aspirated at the bedside but reaccumulated. A repeat aspiration was followed by cranioplasty (22 days post-craniectomy). Postoperative imaging confirmed hygroma resolution (Fig. 1D). Over days the patient's neurological exam improved, his pupillary exam normalized, and he moved all extremities spontaneously. He was weaned from the ventilator and discharged to rehab.

Four months after his initial injury the patient was living at home with normal neurologic exam and GCS 15.

3. Case 2

A 22-year-old male was ejected during a motor vehicle crash. His GCS was 3T on admission and imaging revealed a holo-hemispheric subdural hemorrhage with midline shift (Fig. 2A). After resuscitation his GCS improved to 10T. He was taken for emergent hemicraniectomy. Post-operative imaging showed new hemispheric and falxine subdural hematomas (Fig. 2B).

He remained intubated with GCS 9T and a full, soft flap. His EVD was removed after eight days and his exam slowly improved to where he followed commands, opened eyes spontaneously, and mouthed words. His exam remained stable over the following days, but serial imaging revealed a hygroma without significant midline shift or mass effect, and he remained on the ventilator.

* Corresponding author at: Emory Faculty Office Building, 49 Jesse Hill Drive SE, Room #341, Atlanta, GA 30303, United States. Tel.: +1 404 778 1398; fax: +1 404 778 1307.

E-mail address: faiz.ahmad@emory.edu (F.U. Ahmad).

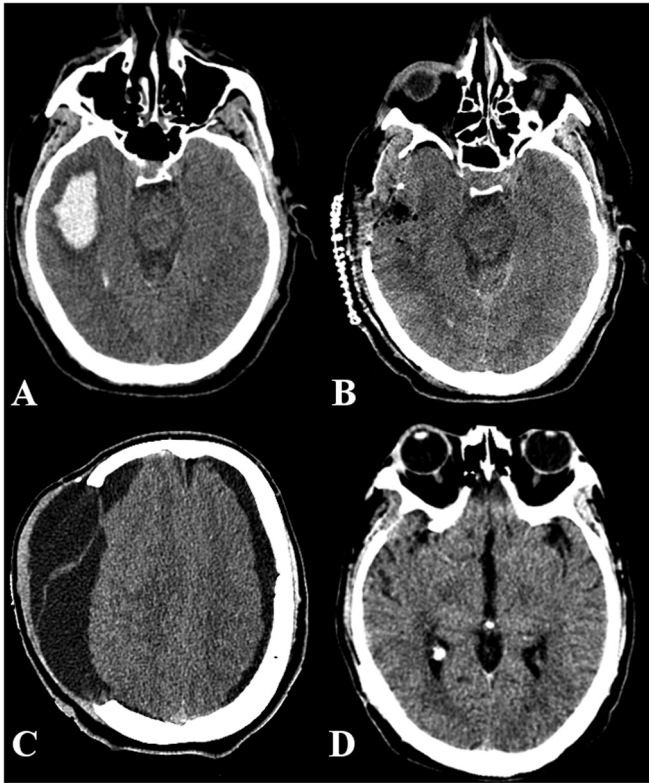


Fig. 1. CT of first case, 43-year-old male after ground level fall. (A) Early imaging shows temporal intraparenchymal hemorrhage (5 × 2 cm). (B) Post-craniectomy flap remained sunken. (C) After neurologic decline and flap bulge were noted, repeat imaging revealed hygroma with midline shift. (D) Cranioplasty was performed 22 days after craniectomy with complete neurologic recovery.

Fifteen days after craniectomy he became agitated and his craniectomy flap was swollen. Imaging showed the hygroma had enlarged to 3 cm (Fig. 2C). This was aspirated (165 cc) but reaccumulated the following day. During this time, his neurologic exam declined, he became drowsier, non-verbal, and only intermittently followed commands. The decision was made to perform cranioplasty (21 days post-craniectomy). Over the following days, he improved to GCS 11T with antigravity strength and was reliably following commands. The remainder of his hospital course was uncomplicated with no collections on follow-up imaging (Fig. 2D). Thirty days after craniectomy he was discharged to home.

Four months after his initial injury he was living at home with no focal neurological deficits and normal postoperative changes on imaging.

4. Discussion

Following decompressive craniectomy the most common complications in the trauma subpopulation are CSF disturbances such as hydrocephalus, fistulas, or most commonly a hygroma [1].

Hemorrhage and fluid collections tend to occur days to weeks after craniectomy while paradoxical herniation tends to occur months later [2,3]. To understand this temporal pattern, studies have examined the effect of cranioplasty finding it improves perfusion and restores autoregulation [7]. While cranioplasty has traditionally been delayed months while edema, fluid collections, and inflammation subside, there has been increasing interest in earlier cranioplasty with some studies reporting greater neurologic improvement [5,6,8,9].

The pathophysiology of these extra-axial collections is unknown; however it has been suggested that a combination of

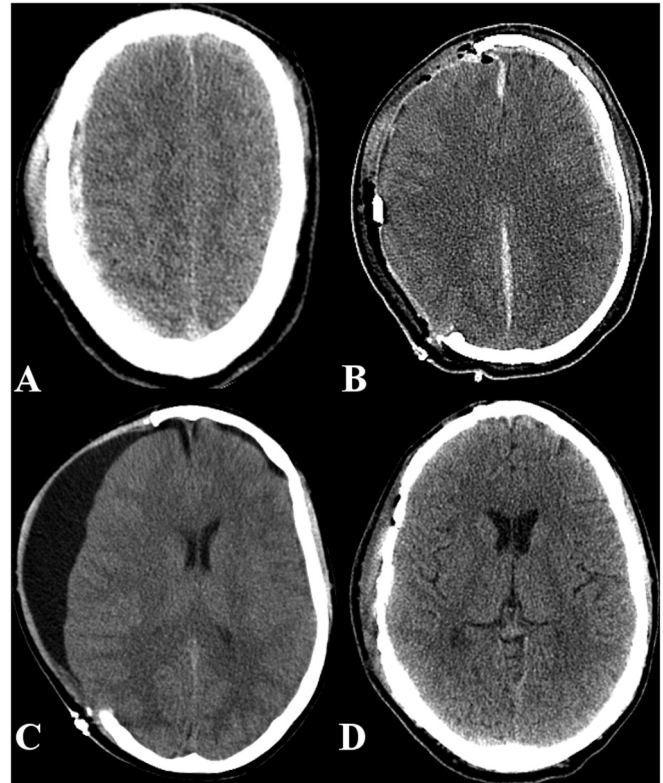


Fig. 2. CT of second case, 22-year-old male after motor vehicle crash. (A) Initial imaging shows 7 mm right holo-hemispheric subdural hemorrhage with midline shift. (B) Post-craniectomy imaging shows new left-sided and falcine subdural hematomas. (C) After neurologic decline, repeat imaging revealed hygroma. (D) Cranioplasty was performed 21 days after craniectomy with complete neurologic recovery.

arachnoid tears, subarachnoid inflammation, damage to arachnoid villi, and the lack of cranial pressure forcing fluid absorption all contribute to their development [10]. We believe that these collections represent a low-pressure phenomenon where CSF flows into the extra-axial space but is unable to egress.

Several studies have analyzed risk factors and management strategies for CSF disturbances. Hygromas have been found to be associated with diffuse, high impact trauma [10,11]. The earliest imaging evidence appears in the first week post-craniectomy, the volume peaks between weeks 3–4, and they tend to resolve by four months with few requiring surgical intervention [11]. The cases presented both developed neurologic symptoms just prior to this peak, but due to their neurologic decline conservative management was tried only briefly.

For patients with hydrocephalus or extra-axial fluid collections, shunting is a common approach [12]; however, collections may still develop [10]. When planning early cranioplasty, patients with high EVD output (>150 cc/day) may require simultaneous shunt placement [13]. In one study a shorter delay resulted in better resolution of post-craniectomy hydrocephalus without need for permanent shunting [12]. Symptomatic contralateral collections may also develop, and when these fail conservative management, early cranioplasty has shown success [10].

After decompressive craniectomy, many patients develop extra-axial CSF collections likely due to the effects of inflammation and injury altering normal CSF circulation. While many of these disturbances resolve spontaneously, some patients develop progressive symptoms. Early cranioplasty may be safe and effective at providing opposing pressure and restoring CSF dynamics.

Notes

There is no financial or material support for this work.

The patients or next of kin have consented to submission of this case report.

References

- [1] Kurland DB, Khaladj-Ghom A, Stokum JA, et al. Complications associated with decompressive craniectomy: a systematic review. *Neurocrit Care* 2015;23:292–304. <http://dx.doi.org/10.1007/s12028-015-0144-7>.
- [2] Stiver SI. Complications of decompressive craniectomy for traumatic brain injury. *Neurosurg Focus* 2009;26:E7. <http://dx.doi.org/10.3171/2009.4.FOCUS0965>.
- [3] Yang XF, Wen L, Shen F, et al. Surgical complications secondary to decompressive craniectomy in patients with a head injury: a series of 108 consecutive cases. *Acta Neurochir (Wien)* 2008;150:1241–7. <http://dx.doi.org/10.1007/s00701-008-0145-9>.
- [4] Ahmad FU, Bullock R. Decompressive craniectomy for severe head injury. *World Neurosurg* 2011;75:451–3. <http://dx.doi.org/10.1016/j.wneu.2010.12.042>.
- [5] Bender A, Heulin S, Röhrer S, et al. Early cranioplasty may improve outcome in neurological patients with decompressive craniectomy. *Brain Inj* 2013;27:1073–9. <http://dx.doi.org/10.3109/02699052.2013.794972>.
- [6] Yadla S, Campbell PG, Chitale R, et al. Effect of early surgery, material, and method of flap preservation on cranioplasty infections: a systematic review. *Neurosurgery* 2011;68:1124–30. <http://dx.doi.org/10.1227/NEU.0b013e31820a5470>.
- [7] Lazaridis C, Czosnyka M. Cerebral blood flow, brain tissue oxygen, and metabolic effects of decompressive craniectomy. *Neurocrit Care* 2012;16:478–84. <http://dx.doi.org/10.1007/s12028-012-9685-1>.
- [8] Chibbaro S, Di Rocco F, Mirone G, et al. Decompressive craniectomy and early cranioplasty for the management of severe head injury: a prospective multicenter study on 147 patients. *World Neurosurg* 2011;75:558–62. <http://dx.doi.org/10.1016/j.wneu.2010.10.020>.
- [9] Chun H-J, Yi H-J. Efficacy and safety of early cranioplasty, at least within 1 month. *J Craniofac Surg* 2011;22:203–7. <http://dx.doi.org/10.1097/SCS.0b013e3181f753bd>.
- [10] Salunke P, Garg R, Kapoor A, et al. Symptomatic contralateral subdural hygromas after decompressive craniectomy: plausible causes and management protocols. *J Neurosurg* 2015;122:602–9. <http://dx.doi.org/10.3171/2014.10.ins.14780>.
- [11] Aarabi B, Chesler D, Maulucci C, et al. Dynamics of subdural hygroma following decompressive craniectomy: a comparative study. *Neurosurg Focus* 2009;26:E8. <http://dx.doi.org/10.3171/2009.3.FOCUS0947>.
- [12] Waziri A, Fusco D, Mayer SA, et al. Postoperative hydrocephalus in patients undergoing decompressive hemicraniectomy for ischemic or hemorrhagic stroke. *Neurosurgery* 2007;61:489–93. <http://dx.doi.org/10.1227/01.NEU.0000290894.85072.37>.
- [13] Carvi Y, Nievas MN, Höllerhage H-G. Early combined cranioplasty and programmable shunt in patients with skull bone defects and CSF-circulation disorders. *Neurol Res* 2006;28:139–44. <http://dx.doi.org/10.1179/016164106X98008>.